



Houttuynia cordata polysaccharides ameliorate pneumonia severity and intestinal injury in mice with influenza virus infection

Haiyan Zhu^{a,1}, Xiaoxiao Lu^{b,1}, Lijun Ling^c, Hong Li^b, Yingye Ou^b, Xunlong Shi^a, Yan Lu^c, Yunyi Zhang^{b,*}, Daofeng Chen^{c,*}

^a Department of Microbiological and Biochemical Pharmacy, School of Pharmacy, Fudan University, Shanghai, China

^b Department of Pharmacology, School of Pharmacy, Fudan University, Shanghai, China

^c Department of Pharmacognosy, School of Pharmacy, Fudan University, Shanghai, China



ARTICLE INFO

Keywords:

HCP
Influenza A virus
Lung injury
Intestine injury
Gut-lung axis

ABSTRACT

Ethnopharmacological relevance: *Houttuynia cordata* is an important traditional Chinese medicine for the treatment of respiratory diseases including bacterial and viral infections. Polysaccharides isolated from *Houttuynia cordata* (HCP), as its main ingredients, have been demonstrated to ameliorate the LPS-induced acute lung injury in mice. The study aimed to determine the protective effects of HCP on multiple organ injury in influenza A virus (IAV) H1N1 infected mice and its primary mechanisms in anti-inflammation and immune regulation.

Materials and methods: Mice were inoculated with IAV H1N1 and then treated with 20 or 40 mg/kg/d of HCP for survival test and acute lung-gut injury test.

Results: The treatment with HCP resulted in an increase in the survival rate of H1N1 infected mice and the protection from lung and intestine injury, accompanied with the reduced virus replication. HCP markedly decreased the concentration of pulmonary proinflammatory cytokines/chemokines and the number of intestinal goblet cells, and strengthened the intestinal physical and immune barrier, according to the increase of sIgA and tight junction protein (ZO-1) in intestine. At the same time, the inhibition of inflammation in lung and gut was related to the suppressing of the expression of TLR4 and p-NFκB p65 in lung.

Conclusions: These results indicated that HCP ameliorated lung and intestine injury induced by IAV attack. The mechanisms were associated with inhibition of inflammation, protection of intestinal barrier and regulation of mucosal immunity, which may be related to the regulation of gut-lung axis. As an alternative medicine, HCP may have clinical potential to treat IAV infection in human beings.

1. Introduction

Influenza A virus (IAV) is a highly contagious respiratory pathogen with a considerable medical and socioeconomic burden and pandemic potential. However, vaccines, antiviral drugs and antibodies cannot protect patients from severe pneumonia completely in clinic. As an important complementary therapy, the immune regulation medicine need to be developed urgently. Many herbal extracts or derivatives have been demonstrated to have potent anti-influenza virus and immunomodulatory effects.

Houttuynia cordata Thunb. (HC, Saururaceae family), which is native to Asia, is an important TCM for the treatment of bacterial pneumonia and viral pneumonia because of its various bioactivities, such as antiviral and antibacterial, anti-inflammatory, anti-complement, anti-allergy, and antioxidant activities (Kim et al., 2008; Lee et al., 2013; Cheng et al., 2014; Li et al., 2005, 2013; Liu et al., 2010; Zhang et al., 2012). Some of the active ingredients of *Houttuynia cordata*, such as volatile oil and flavonoids had made some progresses on anti-inflammatory activities and its anti-inflammatory pathways (Li et al., 2013; Lee et al., 2015; Chun et al., 2014). It had been verified that

Abbreviations: HCP, *Houttuynia cordata* polysaccharides; IAV, influenza A virus; ALI, acute lung injury; MODS, multiorgan dysfunction syndrome and death; ELISA, enzyme linked immunosorbent assay; TNF-α, tumor necrosis factor-alpha; IL-1, interleukin-1; IFN-α, interferon-α; IL-6, interleukin-6; IL-10, interleukin-10; RANTES, regulated on activation normal T cells expressed and secreted; IP-10, interferon-inducible protein-10; MCP-1, monocyte chemoattractant protein-1; MIP-1α, macrophage inflammatory protein-1α; DAB, 3,3'-diaminobenzidine; EDTA, ethylene diamine tetraacetic acid; HRP, horseradish peroxidase; ZO-1, zonula occludens-1, also known as Tight junction protein 1; PAS, periodic acid-Schiff method; TLR4, toll-like receptor 4; NFκB p65, nuclear factor-κB p65; GALT, gut associated lymphoid tissue; DC, dendritic cell; MLN, mesenteric lymph nodes; SDS-PAGE, sodium dodecyl sulfate-polyacrylamide gel electrophoresis

* Correspondence to: Department of Pharmacognosy, School of Pharmacy, Fudan University, 826 Zhangheng Road, Shanghai 201203, China.

E-mail addresses: zhcheng@shmu.edu.cn (Y. Zhang), dfchen@shmu.edu.cn (D. Chen).

¹ These authors contributed equally to this work.

<https://doi.org/10.1016/j.jep.2018.02.016>

Received 10 October 2017; Received in revised form 9 February 2018; Accepted 10 February 2018

Available online 19 February 2018

0378-8741/ © 2018 Elsevier B.V. All rights reserved.

Polysaccharides isolated from *Houttuynia cordata* (HCP) may alleviate LPS induced lung inflammatory injury, which is associated with its inhibitory effect on the over activation of complements and macrophages (Xu et al., 2015). In the acute LPS-attack mouse model with the simulated bacterial infections, the macrophages, complement and other nonspecific immune molecules are involved in the removal bacteria and anti-inflammatory responses during 24 h process. The antiviral defense mechanism is completely different from bacteria infections. In the acute H1N1 -attack mouse model, immune responses involved in interferon, NK cells, T cells, B cells, and their immunopathologic damage in a dynamics process, apart from macrophages and complement. Whether the HCP can treat viral pneumonia induced by influenza virus need to be investigated.

Polysaccharides, as a natural macromolecular polymer, exert activities in blood after gastrointestinal digestion and absorption. We speculated that the interaction between polysaccharides and the intestinal homeostasis, which protect the intestinal barrier and regulate gut immune cell differentiation, were involved in the protection of lung injury induced by IAV. Therefore, in the present study, we evaluated the protective efficacy of HCP by oral administration against H1N1-induced lung and intestinal injury in a mouse model.

Severe influenza can often lead to death in clinics. The most serious complications of viral pneumonia include sepsis and multiorgan dysfunction syndrome (MODS). The mechanism of lethal viral pneumonia has recently been expanded to include secondary infection and multiple organ injuries in influenza virus infected model (Ishikawa et al., 2016; Harada et al., 2016; Deriu et al., 2016). Clinically, influenza patients have some common symptoms such as cough and weakness (Monto et al., 2000), but some patients, especially young children, are often accompanied with gastroenteritis-like symptoms such as abdominal pain, vomiting and diarrhea (Dilantika et al., 2010; Shinde et al., 2009). The gut and lung have a common origin in embryonic developments, involving in the common mucosal immune system. It has also been shown that the intestinal microenvironment changes in the course of several different lung diseases. This indicates that there is a vital cross-talk between these two mucosal sites of the human body (Budden et al., 2017; He et al., 2017). The gut has been referred to as the “motor” of systemic inflammatory response syndrome. However, it remains unknown whether an effective drug with potent antiviral and anti-inflammatory activity attributes to its protection for lung and intestinal injury induced by IAV simultaneously.

In our study, the results showed that multiple organ injury and more complicated mechanisms such as mucosal immune and gut-lung axis were involved in the pathogenesis of viral pneumonia in H1N1-infected mice. Administration of HCP alleviated the lung and gut injury simultaneously. The restoration from intestinal barrier injury may be helpful for alleviating the inflammation in lung, which provided the evidence for regulation of gut-lung axis with the treatment of HCP. These results laid the foundation for the deeper mechanism research about the regulation the homeostasis of gut microbiota. The significance of the research was to light up the characteristics of the HCP in treatment of respiratory diseases.

2. Materials and methods

2.1. Animals and ethics statement

Male BALB/c mice (4–6 weeks) were obtained from Slaccas-Shanghai Lab Animal Ltd. (SPF II; Certificate No. SCXK2012-0002) and housed in collective cages under a 12 h light/dark cycle with free access to food and water. All mice received humane care in compliance with the “Guide for the Care and Use of Laboratory Animals” published by the National Institutes of Health. All study protocols were approved by the Animal Ethical Committee of School of Pharmacy, Fudan University (Approval NO. 2013-50). All surgeries were performed under anesthesia, and efforts were made to minimize suffering.

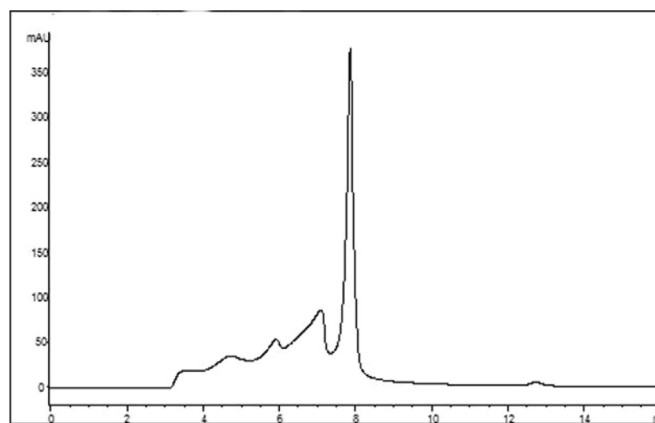


Fig. 1. High-performance gel permeation chromatography (HPGPC) of HCP. HCP was analyzed on a TSK GMPWXL gel filtration column (7.6 mm × 300 mm, TOSOH), eluted with ultrapure water at a flow rate of 1.0 ml/min, and detected at 254 nm. HCP contained one major polysaccharide with several minor ones.

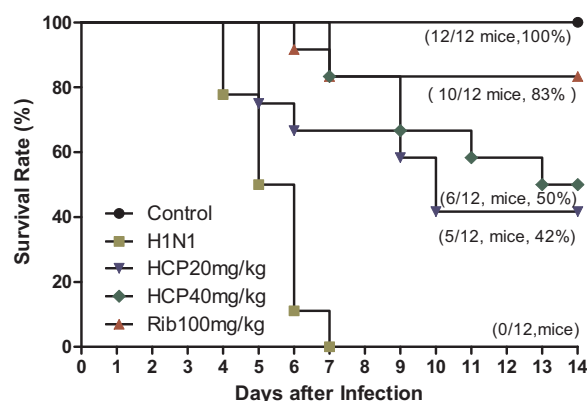


Fig. 2. Effect of HCP on the survival rate of H1N1-infected mice. Mice were infected intranasally with H1N1 at a dose of LD₁₀₀ and then treated with 5‰ CMC (control group and H1N1 group), 20 mg/kg/day of HCP (HCP20 mg/kg group), 40 mg/kg/day of HCP (HCP 40 mg/kg group), or 100 mg/kg/day of ribavirin (Rib100 mg/kg group) for 7 days, then the survival of mice was monitored daily for 14 days after viral infection, and the survival rate was calculated.

2.2. Influenza virus

A mouse-adapted strain of high pathogenicity influenza virus H1N1 A/FM/1/47 supplied by Shanghai Center for Disease Control & Prevention (Shanghai, China) was suspended in RPMI-1640 medium, propagated in lungs of mice and stored at −70 °C until needed. LD₅₀ was measured in mice administered serial dilutions of the stock.

2.3. Reagents

The reagents used in this study included ribavirin (Rib, No. 140629; WeeBeyonnd Scientific & Trade Co. Ltd., Shanghai, China); mouse TNF-α, IL-6, IFN-α, IL-1 (Lot NO. 201303, Jinma Laboratory Equipment Co., Ltd., Shanghai, China); sIgA, MIP-1, RANTES, MCP-1 and IP-10 ELISA kits (Boatman Biotechnology Co. Ltd., Shanghai, China); PAS dye kit (Catalog NO. BA-4080A, Baso Biotechnology Co. Ltd., Zhuhai, China); TLR4 (Catalog NO. AB13556, Abcam); p-NF-κB p65 (Sc-109, Santa Cruz Biotechnology); ZO-1 (Catalog NO. 21773-1-AP, Proteintech Group, Inc); IgA (Catalog NO. A90-103P, Bethyl Laboratories, USA); IgG-HRP (Catalog NO. BS13278, Biogot Technology, Co. Ltd.); HRP-labeled Goat Anti-Rabbit IgG (A0208, Beyotime Institute of Biotechnology, Jiangsu, China); Chemiluminescent detection kit (Pierce, Rockford, IL).

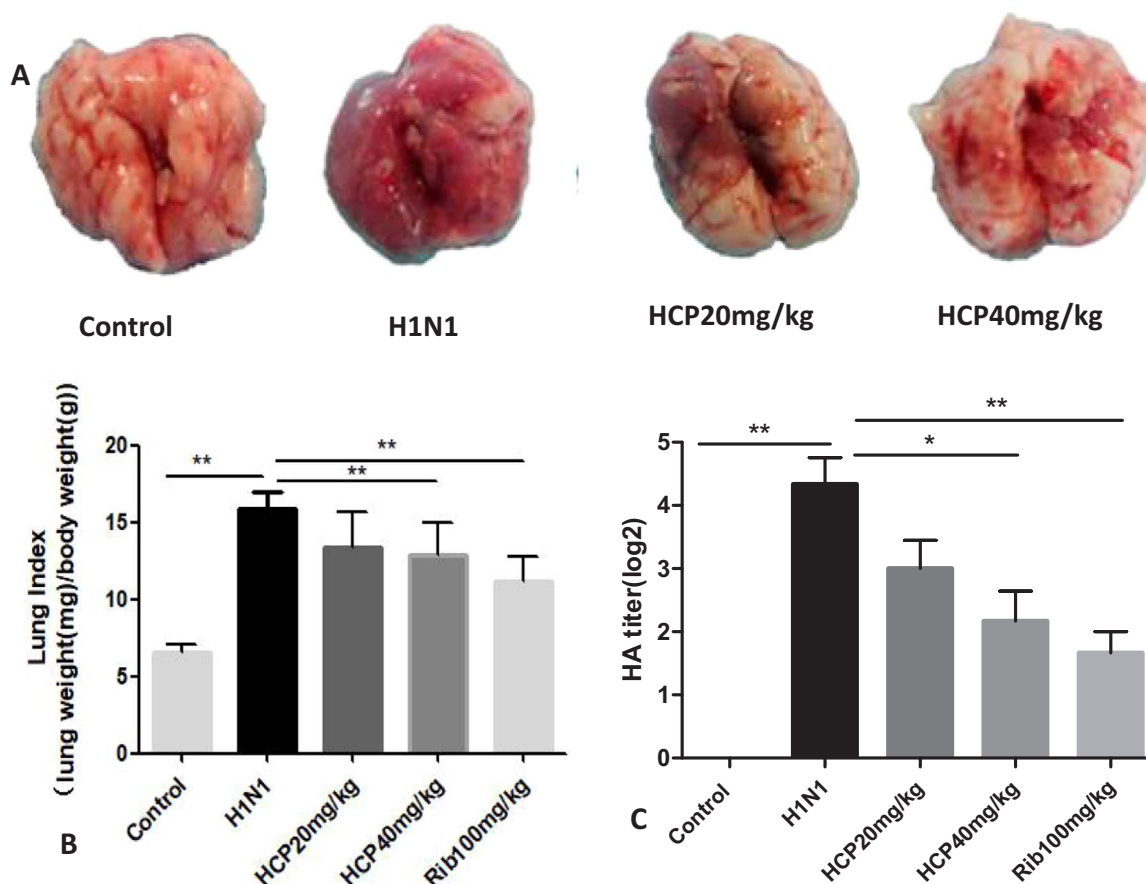


Fig. 3. HCP alleviated the severity of H1N1-induced lung injury and inhibited IAV replication in lungs of infected mice. (A) Macroscopic appearance of lungs; (B) Lung index; (C) HA test. Mice infected with H1N1 were treated intragastrically with HCP, and then sacrificed by euthanasia 4 days later. Lungs were removed and photographed to evaluate the severity of pathological injury (A), and then weighed the lung to calculate the lung index (B). Lungs were homogenized in PBS, and the homogenates were serially diluted 2-fold for HA test. HA titers were expressed as the maximum dilution that caused complete agglutination (C). * $P < 0.05$, ** $P < 0.01$ compared with the virus control group. Each bar represents mean \pm SD of 8 mice.

2.4. Preparation and characterization of HCP

The dried whole plant of *Houttuynia cordata* Thunb. (*Saururaceae*) was purchased from Shanghai Hua-Yu Chinese Materia Medica Co. Ltd. and was identified by one of the authors (Dr. Yan Lu). A voucher specimen (DFC-YXC-2006072601) has been deposited at the Department of Pharmacognosy, School of Pharmacy, Fudan University, Shanghai, China. The dried whole plant of *H. cordata* was ground and defatted with 95% ethanol, and the residue was extracted with hot water. The water extract was concentrated and precipitated with trichloroacetic acid to remove proteins. The supernatant was dialyzed against running water for 3 d, and then precipitated with 4 volumes of 95% ethanol. The precipitate was lyophilized to yield HCPs. The total carbohydrate content was determined by the phenol-sulfuric acid method with D-galactose as the standard. The uronic acid content was determined by the m-hydroxybiphenyl method with D-galacturonic acid as the standard. The total protein concentration was determined by the Coomassie brilliant blue method with bovine serum albumin as the standard. HCP was dissolved in 5‰ CMC solution and administered orally by gavage.

2.5. Survival rate test

BALB/c mice were randomly divided into five groups: Normal group, H1N1 group, H1N1 + 20 mg/kg of HCP group, H1N1 + 40 mg/kg of HCP group, and H1N1 + 100 mg/kg of Rib group. Mice were anesthetized with diethyl ether, and then inoculated intranasally with H1N1 at a dose of LD_{100} (equivalent to 10^{-4} dilution of storage liquid) suspended in 30 μ l of RPMI-1640 medium. The day of virus inoculation

was defined as day 0. Treatment was initiated 2 h after virus infection. Mice were gavaged once daily with 5‰ CMC and medicine from day 0 to day 7 ($n = 12$) separately. The survival rate of mice was monitored after virus infection during 14 days (Chen et al., 2015).

2.6. Establishment of IAV infected acute lung injury

The experimental group scheme in the acute lung injury test was the same as 2.5. Mice were inoculated intranasally with H1N1 at a dose of $2LD_{50}$ (equivalent to 5×10^{-5} dilution of storage liquid). Treatment was initiated 2 h after virus infection. Mice were gavaged once daily from day 0 to day 4 ($n = 6$). The lung and intestine were removed on day 4 for weighing and store for subsequent analysis (Chen et al., 2015).

2.7. Pathological and immunohistochemical analyses

Lung and intestine were removed on day 4 after infection. Left lung lobes and 1 cm of intestine were inflated with 10% phosphate-buffered formalin to their normal volume, paraffin embedded and cut into 4- μ m thick sections. One section from each tissue sample was stained using a standard haematoxylin-and-eosin (HE) protocol and the periodic acid-Schiff (PAS) method to visualize pathological changes in lung and intestine and goblet cells in intestine. Lung and intestine sections were examined to determine the severity of pneumonia in a blinded fashion as previously described.

Immunohistochemistry (IHC) staining was performed as previously described. High temperature antigen retrieval was performed by

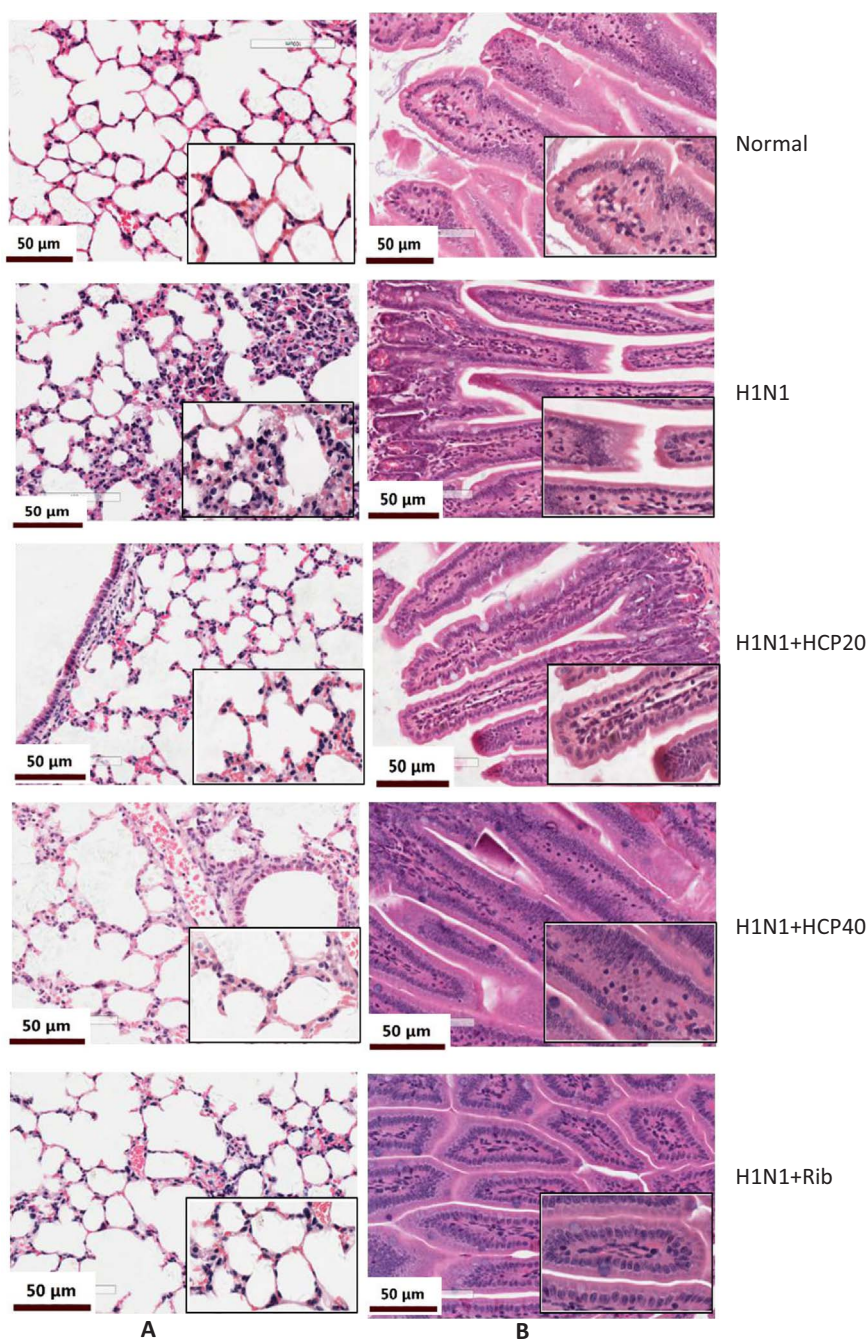


Fig. 4. The effect of HCP on histopathological changes in lung (A) and intestine (B) of H1N1-infected mice on day 4 after infection. Mice infected with H1N1 or RMP1 1640 were treated intragastrically with HCP and Ribavirin daily for 4 days, and then sacrificed by euthanasia to harvest tissues. H&E staining was performed to determine histopathological changes (Light microscopy 200 × and 400 ×). Mice showed severe infiltration of monocytes and lymphocytes, thickened alveolar walls in lung (A), intestinal mucosa edema, part of intestinal villus breakage and narrower intestinal tract (B) in the virus control group on day 4 after infection.

immersing deparaffinized slides in 10 mM trisodium citrate buffer (pH 6.0) in a water bath at 99 °C for 20 min. Endogenous peroxidase was quenched with 3% hydrogen peroxide in methanol (v/v) for 15 min, and then non-specific binding sites were blocked with 5% BSA. After the removal of BSA, the sections were incubated with primary antibody p-NF-κB p65, TLR4, IgA or ZO-1 at 4 °C overnight in a humidified chamber, and then incubated with HRP-conjugated goat anti-rabbit or anti-mouse IgG antibody at 37 °C for 30 min. IHC staining of IgA was performed following the manufacturer's instructions. After quenching of endogenous peroxidase, the sections were blocked with 5% BSA for 30 min and then incubated with HRP-conjugated goat anti-rabbit IgA antibody at 4 °C overnight in a humidified chamber. Slides were

visualized using chromogenic substrate solution DAB and counterstained with hematoxylin, and then observed under a microscope (Xu et al., 2015).

2.8. Western blotting assay

The lung proteins were prepared using RIPA lysis kit (Beyotime Institute of Biotechnology, Jiangsu, China). The protein concentration was examined by the bicinchoninic acid (BCA) method. Equivalent amounts of protein were separated by sodium dodecyl sulfate-polyacrylamide gel electrophoresis (SDS-PAGE) and then transferred to poly-vinylidene fluoride membranes. The membranes were blocked in

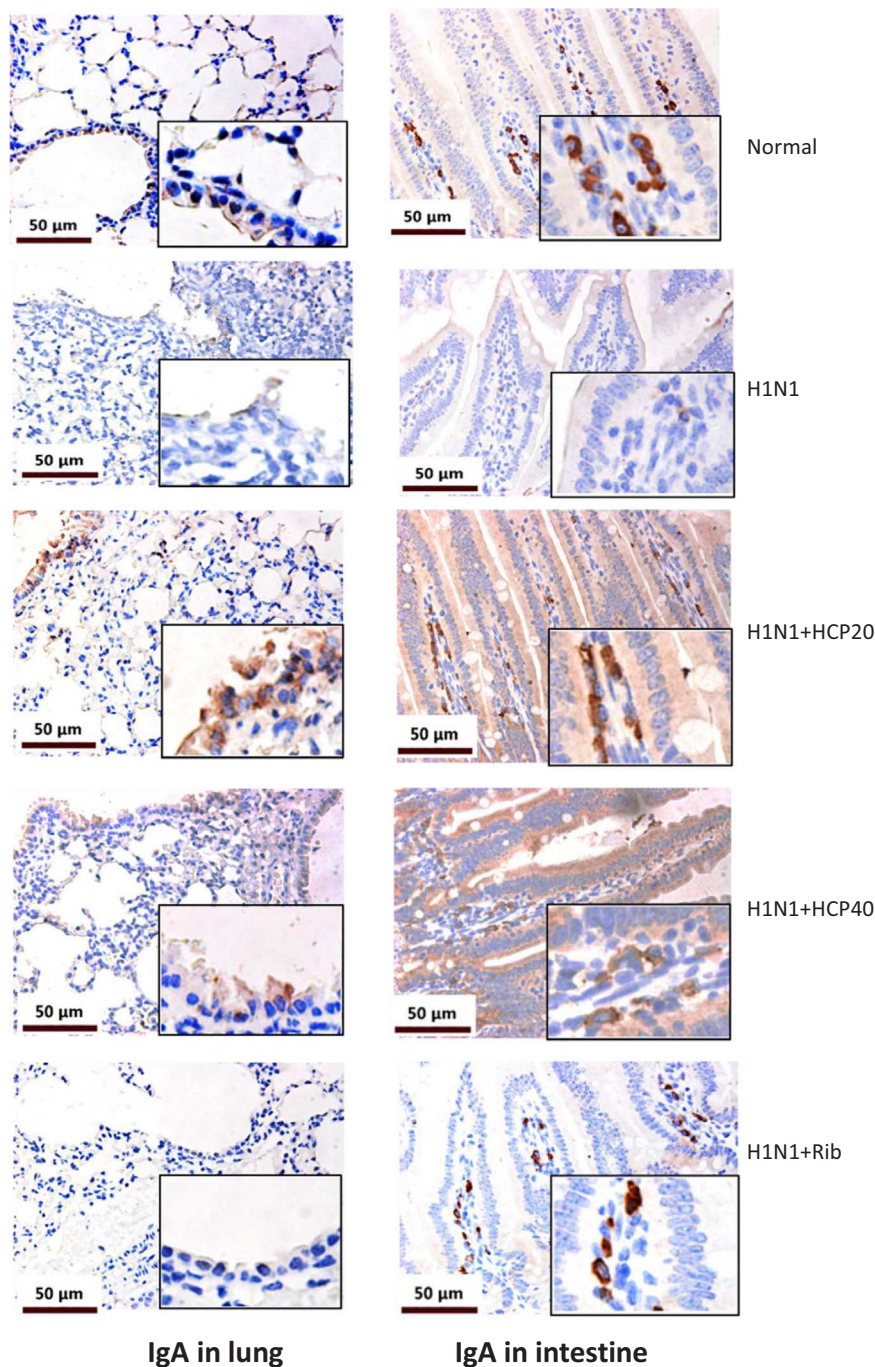


Fig. 5. Effects of HCP on IgA expression in lung and intestine of H1N1-infected mice. The test process was the same as described in Fig. 4. IgA expression was detected in lung and small intestine using IHC analysis (Light microscopy 200 × and 400 ×).

Tris-buffered saline and Tween 20 (TBST) containing 3% bovine serum albumin (BSA) for 1 h at room temperature, and incubated with the primary antibodies (TLR4 and p-NF-κB p65 at 1:1000) at 4 °C overnight and then with HRP-labeled Goat Anti-Rabbit IgG with horseradish peroxidase for 1 h at room temperature. Then, the membranes were washed in TBST and the signals were visualized using an enhanced chemiluminescent detection kit (Pierce). Densitometric values of protein bands were quantified by the IQuantTL software (GE Healthcare, USA) (Chen et al., 2015).

2.9. Hemagglutination titer assay

The virus titer in lung homogenates obtained from H1N1-infected

mice was determined on day 4 after infection. The viral load in lung tissues was presented as hemagglutinin (HA) titer. Briefly, each lung was homogenized to moderate volume suspension with PBS, and 50 microliters of homogenates were serially diluted (2-fold) in V-bottom 96-well plates and mixed with 50 μl of 1% chicken red blood cell suspension. Plates were incubated at room temperature for 30 min. The HA titer was expressed as the maximum dilution times in which agglutination was observed.

2.10. Measurement of inflammatory cytokines/chemokines in lung homogenates

Mice were euthanized on day 4 after IAV infection. Lung

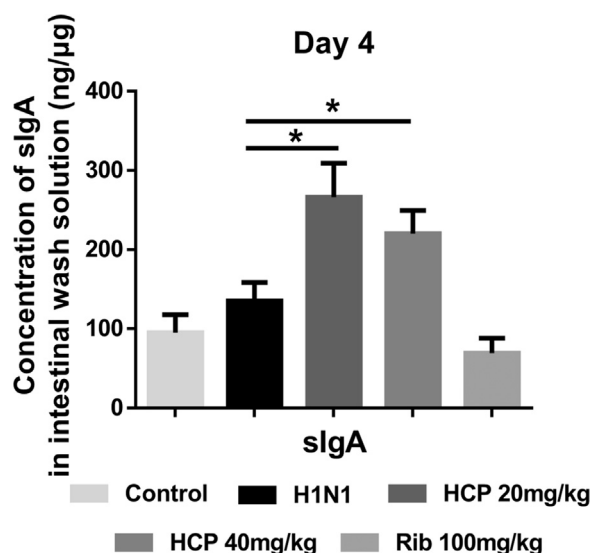


Fig. 6. Effects of HCP on sIgA secretion of gut in H1N1-infected mice. The test process was the same as described in Fig. 4. The sIgA secretion in small intestine was solution was investigated using ELISA analysis. * $P < 0.05$ indicate degrees of statistical significance of difference as compares to the virus control group.

homogenates were prepared at a concentration of 100 mg tissue/ml PBS, and the cytokine/chemokine protein expression was determined. The levels of IFN- α , TNF- α , IL-6, RANTES, IL-1, IP-10, MCP-1 and MIP-1 α in lung homogenates were assayed using specific sandwich ELISA kits according to the manufacturer's instructions. The concentration of sIgA was assayed and calibrated by per μ g protein in intestinal wash solution using ELISA kits.

2.11. Statistical analyses

All statistical analyses were performed using GraphPad Prism 5.0 software (Graph Pad Software, Inc, CA, USA). Survival curves were estimated by the Kaplan-Meier method and their homogeneity was estimated by the log-rank test. Multiple group comparisons were performed using one-way analysis of variance (ANOVA), followed by Dunnett's test to determine significant differences from the control. A P value less than 0.05 was considered significant.

3. Results

3.1. Characterization of HCP

The HCP yield was 3.68% of dry material. It is a dark brown water-soluble powder. The content of carbohydrate, uronic acid, and total protein is $77.21 \pm 2.84\%$, $36.69 \pm 4.94\%$ and $6.17 \pm 1.93\%$, respectively ($n = 3$). Fig. 1 shows one major peak in the chromatogram of high-performance gel permeation chromatography (HPGPC). GC analysis showed that HCP was mainly composed of glucose, galactose, arabinose and rhamnose in a ratio of 3.40: 2.14: 1.17: 1 with trace amounts of mannose and xylose.

3.2. HCP improved the survival of IVA infected mice

The therapeutic potential of HCP against IAV infection was evaluated in a mouse model of LD₁₀₀ H1N1 infection. The results showed that infection with a lethal dose of IVA led to the death of all mice within 14 days. Mice showed signs of piloerection, lethargy, weight loss and reduced food intake 3 days after H1N1 inoculation, and some of them died within 7–11 days of infection. Fig. 2 shows that the survival rate was 0% in the virus control group, but increased to 50%, 42% and 83% on 14 d in the H1N1 + 40 mg/kg of HCPs group, H1N1 + 20 mg/

kg of HCPs group and H1N1 + 100 mg/kg of Rib, respectively.

3.3. HCP protected against pulmonary injury in IAV infected mice

To determine whether HCP could protect against IAV induced pulmonary injury, BALB/c mice were infected with 2LD₅₀ of H1N1. It showed that H1N1 infection resulted in a decrease of body weight but an increase of lung tissue weight. The main pathological damage observed in IAV infected mice was viral interstitial pneumonia on the 4th day after virus inoculation. The lung index (the ratio of lung weight and body weight) in the H1N1 group was increased, indicating that H1N1 infection could cause swelling of lung tissues (Fig. 3A and B). In addition, most H1N1-infected mice showed severe infiltration of monocytes and lymphocytes, thickened alveolar walls, and exudation of inflammatory cells into the alveolar space (Fig. 4). The treatment with 40 mg/kg/day of HCPs resulted in a significant decrease in the number of influenza-related focal lesions and lung consolidation (Fig. 4) and the lung index (Fig. 3B) with suppressing the infiltration of monocytes and lymphocytes, and an inhibition of the expression of the IgA in lung (Fig. 5). The concentration of sIgA was low in lung, and HCP increased the secretion of sIgA in lung with no significance (data not shown).

3.4. HCP inhibited influenza virus replication in vivo

HA titer in lung was determined in order to verify whether HCP attenuated viral replication in the respiratory tract in vivo. HA is the predominant surface glycoprotein of influenza virus, and its expression is positively correlated with copies of influenza virus. Fig. 3C shows that HA titers were significantly higher in H1N1-infected mice than in normal control mice and those mice treated with 40 mg/kg/day of HCP ($P < 0.01$).

3.5. HCP treatment reduced small intestinal barrier injury in IVA infected mice

To test whether intestinal injury occurred in the mice of IAV infection, the same animal model was used as described in Section 3.3. Severe lung and intestine injury was observed after IAV infection (Fig. 4). Mild diarrhea occurred in infected mice on the 4th day after infection, accompanied with some pathological damages including intestinal mucosa edema, intestinal villus breakage and narrower intestinal tract. HCP markedly ameliorated the pathological injury induced by H1N1 in a dose-dependent manner. The treatment with HCP significantly increased the IgA expression in the mucous, sIgA secretion in intestinal tissues (Figs. 5 and 6) and the expression of tight junction protein (ZO-1), and a decreased in the number of goblet cells in tract mucous tissues (Fig. 7). So, all these results demonstrated that HCP effectively protected the mechanical and the immune barrier.

3.6. HCP inhibited the expression of TLR4 and NF- κ B in H1N1-infected mice

NF- κ B is an important transcription factor for the induction of various inflammation-associated genes, regulating cytokines and chemokines. To better understand the therapeutic mechanism of HCP in H1N1-infected mice, we measured the expressions of TLR4 and p65 NF- κ B in lung tissues on the day 4 post infection using Western blot analysis and IHC staining. In Fig. 8, both IHC and WBs showed that H1N1 infection resulted in a significant increase in the expressions of TLR4 and NF- κ B. and HCP down-regulated their expressions in a dose-dependent manner. The results of IHC test and WB test was consistent.

3.7. HCP inhibited cytokine/chemokine burst in lungs of H1N1-infected mice

Influenza virus infection is known to be able to induce a strong

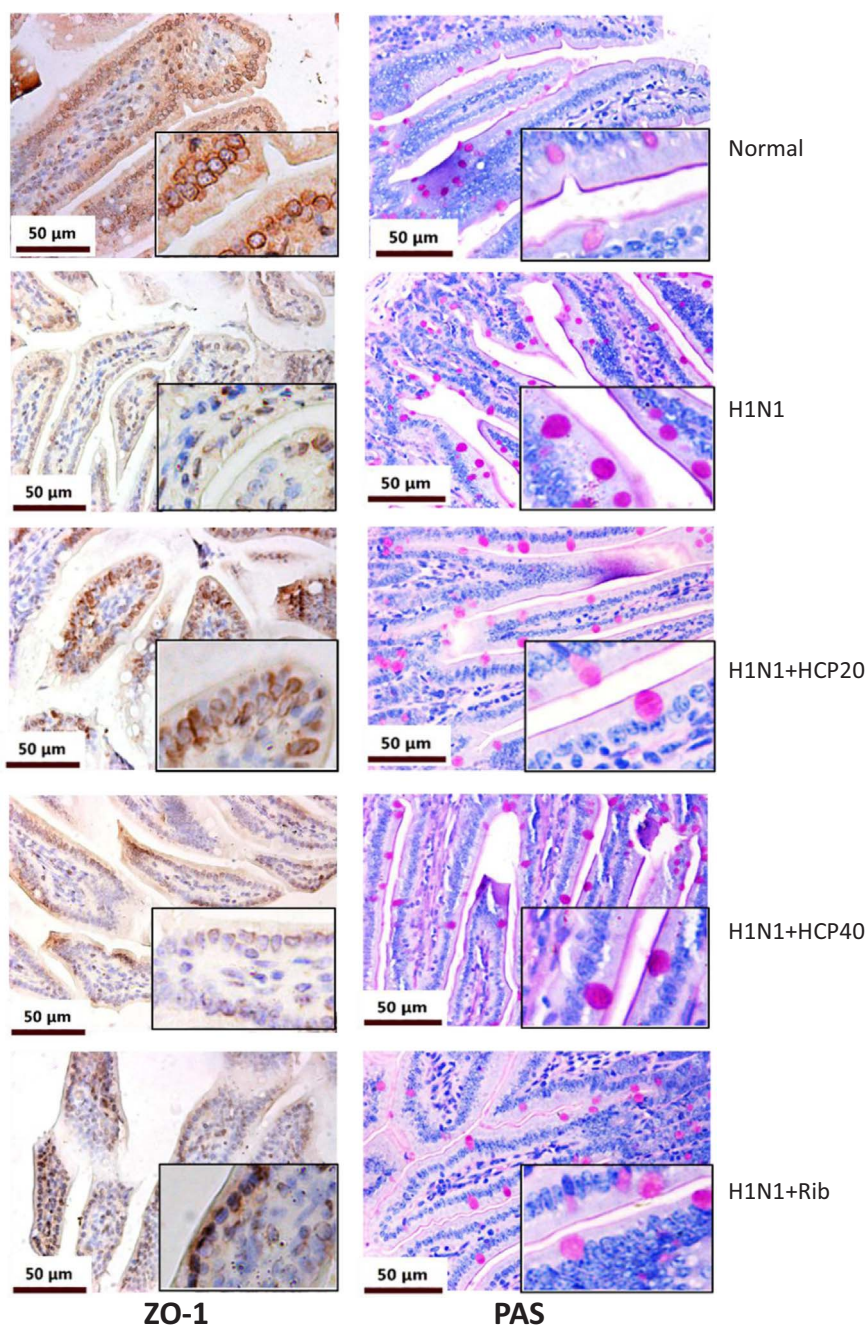


Fig. 7. Effects of HCP on tight junction expression in lung and intestine of H1N1-infected mice. The test process was the same as described in Fig. 4. The levels of ZO-1 and PAS were detected using IHC analysis (Light microscopy 200 × and 400 ×).

inflammatory reaction, hallmarked by the production of cytokines and chemokines. Lungs were harvested on the day 4 after infection for the measurement of cytokines/chemokines. Figs. 9 and 10 show that the treatment with 40 mg/kg/day of HCP could significantly inhibited the production of TNF- α , IL-6, IFN- α , RANTES, MCP-1, MIP-1 α and IP-10. In addition, the IL-1 concentration was slightly but not significantly lowered in HCP-treated mice after H1N1 infection. Quantitative analysis showed that HCP treatment reduced cytokines in a dose-dependent manner and inhibited the release of excessive cytokines/chemokines from innate immune cells and epithelial cells.

4. Discussion and conclusion

4.1. Discussion

In china, HC as a traditional medicine, is used as a folk therapy against influenza, allergy, asthma Jian et al. (2014), and has the anti-inflammatory activity (Lee et al., 2013). Polysaccharides are major components in the decoction and have remarkable therapeutic effects and relatively low toxicity (Xu et al., 2015). In our study, we verified that the therapeutic effect of HCP on pulmonary and intestinal injury induced by IAV H1N1. The results showed that HCP significantly improved the survival rate of mice infected with a lethal dose of IAV, alleviated the inflammatory injury of pulmonary interstitium, and indirectly reduced virus titers. Interestingly, we found that pathological changes in lung tissues, such as congestion, edema and inflammatory

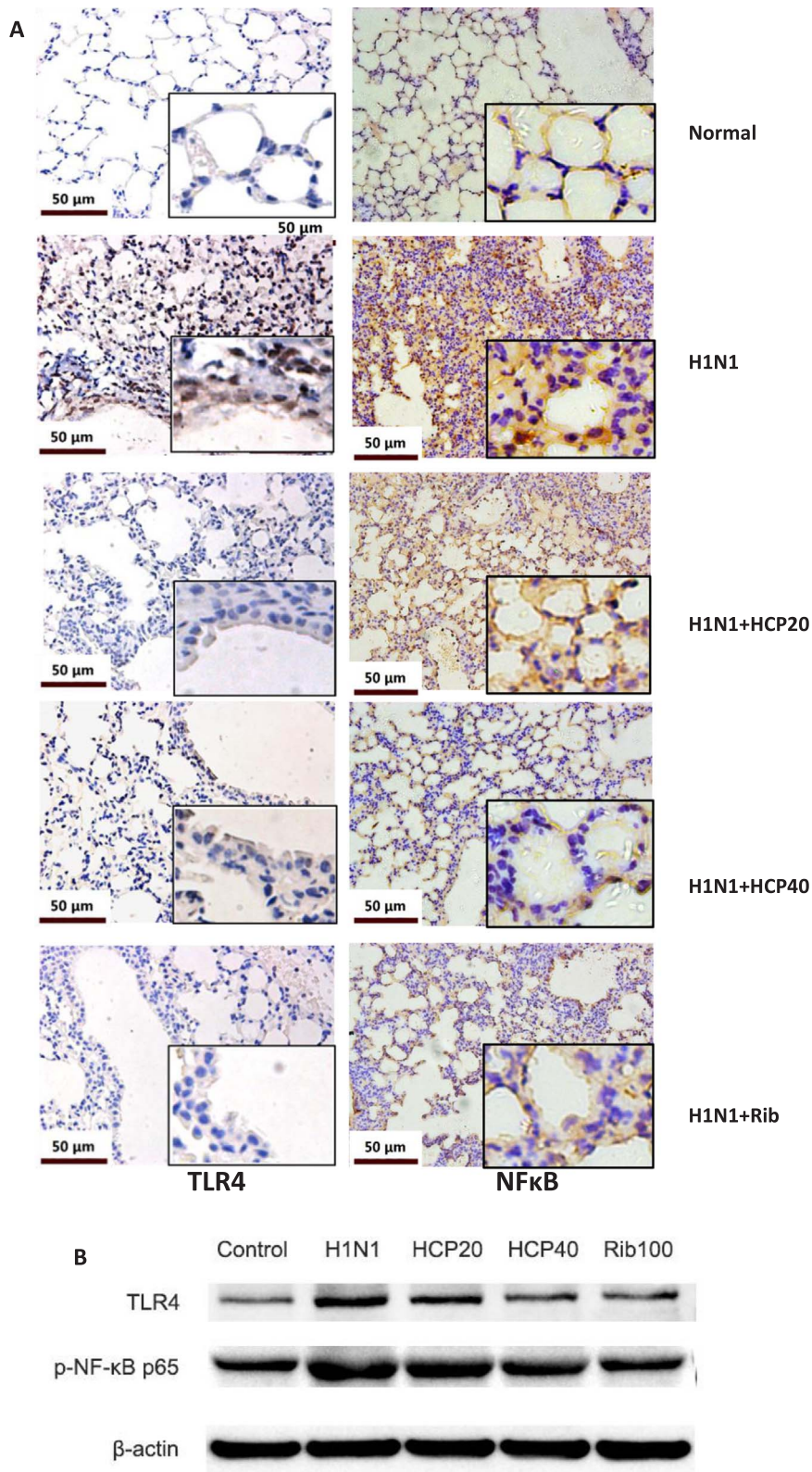


Fig. 8. Effects of HCP on TLR4 and NFκB expression in lung of H1N1-infected mice. The test process was the same as described in Fig. 4. The levels of TLR4 and NFκB in lung tissues were detected using IHC analysis(Light microscopy 200 × and 400 ×) (A) and WB test (B).

exudation, were usually accompanied with intestine injury, such as increased intestinal permeability and the number of goblet cells and decreased ZO-1 protein in H1N1 infected murine model. However, the lung and gut injury was ameliorated simultaneously by the HCP treatment. In addition, the IgA expression and the secretion of sIgA

increased in intestine of HCP-treated mice, which indicated that mucosal immune was involved in the pathological mechanism of lung-gut injury induced by IAV infection.

An increasing number of studies have revealed the immunological relationship between lung and gut. Both lung and gut originate

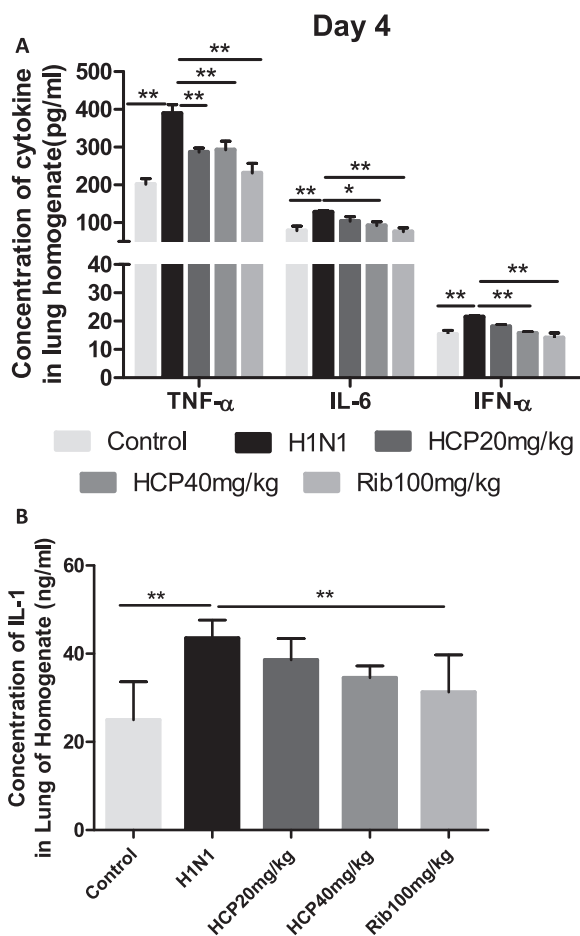


Fig. 9. Effects of HCP on pro-inflammatory cytokine expression in lung of H1N1-infected mice. (A) TNF-α, IL-6, IFN-α, and (B) IL-1 in lung homogenates were determined using ELISA. The results represent the mean of 8 mice. Data are presented as Mean ± SD. *P < 0.05, **P < 0.01 as compared with the virus control group.

embryologically from the same germinal layer and are involved in the mucous immune (Barfod et al., 2013; Segal and Blaser, 2014; Wang and Tian, 2015; Kawase et al., 2012). Although intestine is not the host of IAV, the mucosa of lung and gut are involved in the immune injury in IAV H1N1 infected mice. However, Gut–lung cross-talk during respiratory disease is poorly understood, the correlative study will provide insight into the pathological mechanisms of influenza. Jian et al. (2014) have demonstrated that IAV induced both lung and intestinal injury via microbiota mediated Th17 cell-dependent inflammation in a murine model. IAV H1N1 could replicate in pulmonary epithelial and macrophage cells, which excessively activate the innate immune and recruit macrophages, neutrophils granulocytes and NK cells to kill and clear infected cells. The impairment of respiratory function may result in a decrease in the partial pressure of blood oxygen and consequently the dysfunction of microcirculation. Gut is an organ sensitive to anoxia and ischemia. Intestinal barrier could be impaired due to secondary intestinal anoxia and ischemia after pulmonary infection. It is clear that increased gut permeability and bacterial translocation play a role in multiple organ failure. In the H1N1-infected mouse model, the failure of gut barrier is central to the hypothesis that toxins escaping from the gut lumen contribute to the activation of host immune inflammatory defense mechanisms (Swank et al., 1996). H1N1-infected mice showed weight loss and gastroenteritis-like symptoms, such as reduced appetite and diarrhea. Microscopic pathology showed impaired intestinal barrier, such as decreased ZO-1 expression and increased number of goblet cells. Interestingly, both lung and gut were damaged in H1N1 infected mice. Poroyko et al. (2015) showed that the morbid transformation of

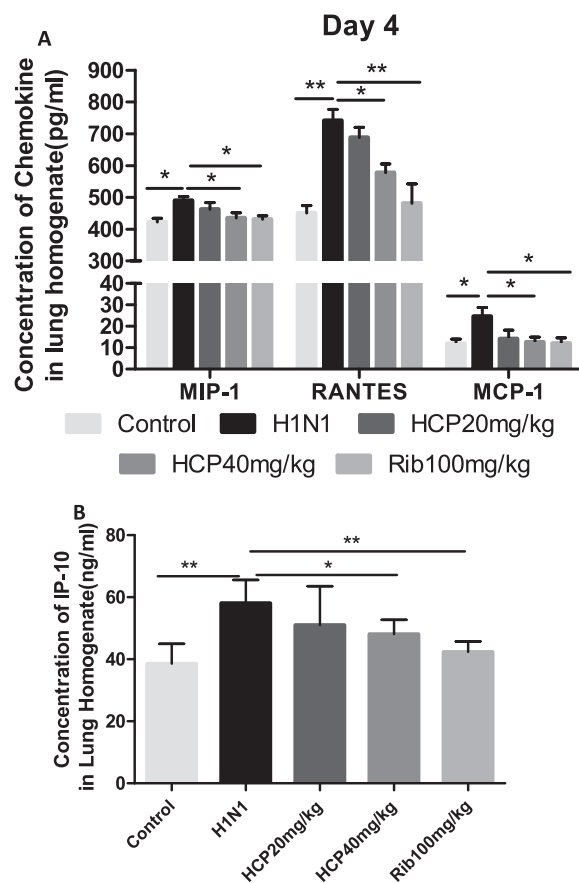


Fig. 10. Effects of HCP on the expression of chemokines in lung of H1N1-infected mice. (A) RANTES, MCP-1, MIP-1α, and (B) IP-10 in lung homogenates were determined using ELISA. The results represent the mean of 8 mice. Data are presented as Mean ± SD. *P < 0.05, **P < 0.01 as compared with the virus control group.

acute lung injury was attributed to the set of inborn opportunistic pathogens thriving in the environment of inflamed lung, rather than the external infectious agents in a mouse model of LPS attack. In our study, IAV as an inhaled antigen induces pathological changes in lung and gut with a high expression of TLR4 and NF-κB (Ludwig et al., 2008). TLR4 can be activated by endogenous “danger signal” molecules released following cellular injury. The activation of the TLR4-NF-κB pathway triggered cascade of inflammatory reactions, indicating that pathogenic bacteria were involved in lung injury. Recent research has shown that gut flora was responsible for inducing lung inflammatory reaction against bacterial challenge and enhancing neutrophils infiltration through TLR4 in mice (Tsay et al., 2011). Thus, we speculated that the destruction of gut homeostasis contributed to IAV induced acute lung injury.

It has been demonstrated that H1N1 virus could not directly infect and replicate in human gut tissues (Wang et al., 2014). Cytokines released from Th17 after virus infection could reach to the intestinal mucosa, thus cause damage to the gut (Wang et al., 2014). When the intestine barrier was damaged, pathogenic intestinal bacteria were exposed and transferred by M cells in lymphoid follicle epithelium, then presented to gut associated lymphoid tissue (GALT) by DC cells, which activated the T subgroup in mesenteric lymph nodes (MLN) and produced regulatory cytokines. Meanwhile, T cell subgroup in GALT and MLN can be recruited to respiratory mucosa by CCR9, as immune homing molecule (Wang et al., 2014). Thus, Intestinal mucosal immune as the center of lung-gut axis affects the lung and intestine together. The mechanisms of mucosa immune regulation of HCP deserved to further investigation.

4.2. Conclusion

Our current study focused on the protective effect of HCP on multiple organ injury induced by influenza virus infected. The results showed that HCP alleviated the IAV-induced lung and gut pathological injury and increased the survival rate through inhibition of the release of pulmonary inflammatory cytokine and expression of TLR4-NF- κ B and improvement of damaged immune and physical gut barrier. Combined with previous studies and current results, we speculated that the anti-inflammatory mechanism of HCP was a complicated process and in connection with the gut-lung axis. What is the interaction between HCP and homeostasis of gut microbiota, and how mucosa immune is involved in this process need further investigation. However, HCP serving as an alternative medicine provides a potentia clinicaltherapy to treat IAV infection in human beings.

Acknowledgements

This work was supported by the National Natural Science Foundation of China (81330089,81673713) and the Ministry of Science and Technology of China (2017ZX09305003).

References

- Barfod, K.K., Roggenbuck, M., Hansen, L.H., Schjørring, S., Larsen, S.T., Sørensen, S.J., Krogfelt, K.A., 2013. The murine lung microbiome in relation to the intestinal and vaginal bacterial communities. *BMC Microbiol.* 13, 303–314.
- Budden, K.F., Gellatly, S.L., Wood, D.L., Cooper, M.A., Morrison, M., Hugenholtz, P., Hansbro, P.M., 2017. Emerging pathogenic links between microbiota and the gut-lung axis. *Nat. Rev. Microbiol.* 15, 55–63.
- Chen, L.J., Yan, X., Yan, Q.L., Fan, J.J., Huang, H., Shi, X., Han, L., Han, T.X., Zhu, H.Y., 2015. The modified JiuWei QiangHuo decoction alleviated severe lung injury induced by H1N1 influenza virus by regulating the NF- κ B pathway in mice. *Evid. Based Complement Altern. Med.* <http://dx.doi.org/10.1155/2015/790739>.
- Cheng, B.H., Chan, J.Y., Chan, B.C., Lin, H.Q., Han, X.Q., Zhou, X., Wan, D.C., Wang, Y.F., Leung, P.C., Fung, K.P., Lau, C.B., 2014. Structural characterization and immunomodulatory effect of a polysaccharide HCP-2 from *Houttuynia cordata*. *CarbohydrPolym* 103, 244–249.
- Chun, J.M., Nho, K.J., Kim, H.S., Lee, A.Y., Moon, B.C., Kim, H.K., 2014. An ethyl acetate fraction derived from *Houttuynia cordata* extract inhibits the production of inflammatory markers by suppressing NF- κ B and MAPK activation in lipopolysaccharide-stimulated RAW 264.7 macrophages. *BMC Complement Altern. Med.* 14, 234.
- Dilantika, C., Sedyaningsih, E.R., Kasper, M.R., Agtini, M., Listyaningsih, E., Uyeke, T.M., Burgess, T.H., Blair, P.J., Putnam, S.D., 2010. Influenza virus infection among pediatric patients reporting diarrhea and influenza-like illness. *BMC Infect. Dis.* 10, 3–7.
- Deriu, E., Boxx, G.M., He, X., Pan, C., Benavidez, S.D., Cen, L., Rozengurt, N., Shi, W., Cheng, G., 2016. Influenza virus affects intestinal microbiota and secondary salmonella infection in the gut through type I interferons. *PLoS Pathog.* 5, e1005572.
- Harada, T., Ishimatsu, Y., Hara, A., Morita, T., Nakashima, S., Kakugawa, T., Sakamoto, N., Kosai, K., Izumikawa, K., Yanagihara, K., Mukae, H., Kohno, S., 2016. Premedication with clarithromycin is effective against secondary bacterial pneumonia during influenza virus infection in a pulmonary emphysema mouse model. *J. Pharmacol. Exp. Ther.* 358, 457–463.
- He, Y., Wen, Q., Yao, F., Xu, D., Huang, Y., Wang, J., 2017. Gut-lung axis: the microbial contributions and clinical implications. *Crit. Rev. Microbiol.* 43, 81–95.
- Ishikawa, H., Fukui, T., Ino, S., Sasaki, H., Awano, N., Kohda, C., Tanaka, K., 2016. Influenza virus infection causes neutrophil dysfunction through reduced G-CSF production and an increased risk of secondary bacteria infection in the lung. *Virology* 499, 23–29.
- Kawase, M., He, F., Kubota, A., Yoda, K., Miyazawa, K., Hiramatsu, M., 2012. Heat-killed *Lactobacillus gasseri* TMC0356 protects mice against influenza virus infection by stimulating gut and respiratory immune responses. *FEMS Immunol. Med. Microbiol.* 64, 280–288.
- Kim, G.S., Kim, D.H., Lim, J.J., Lee, J.J., Han, D.Y., Lee, W.M., Jung, W.C., Min, W.G., Won, C.G., Rhee, M.H., Lee, H.J., Kim, S., 2008. Biological and antibacterial activities of the natural herb *Houttuynia cordata* water extract against the intracellular bacterial pathogen salmonella within the RAW 264.7 macrophage. *Biol.,Pharm. Bull.* 31, 2012–2017.
- Lee, H.J., Seo, H.S., Kim, G.J., Jeon, C.Y., Park, J.H., Jang, B.H., Park, S.J., Shin, Y.C., Ko, S.G., 2013. *Houttuynia cordata* Thunb inhibits the production of proinflammatory cytokines through inhibition of the NF κ B signaling pathway in HMC1 human mast cells. *Mol. Med. Rep.* 8, 731–736.
- Lee, J.H., Ahn, J., Kim, J.W., Lee, S.G., Kim, H.P., 2015. Flavonoids from the aerial parts of *Houttuynia cordata* attenuate lung inflammation in mice. *Arch. Pharm. Res.* 38, 1304–1311.
- Li, G.Z., Chai, O.H., Lee, M.S., Han, E.H., Kim, H.T., Song, C.H., 2005. Inhibitory effects of *Houttuynia cordata* water extracts on anaphylactic reaction and mast cell activation. *Biol. Pharm. Bull.* 28, 1864–1868.
- Liu, F.Z., Shi, H., Shi, Y.J., Liu, Y., Jin, Y.H., Gao, Y.J., Guo, S.S., Cui, X.L., 2010a. Pharmacodynamic experiment of the antiviral effect of *Houttuynia cordata* injection on influenza virus in mice. *Yao XueXueBao* 45, 399–402 (text in chineses).
- Li, W., Fan, T., Zhang, Y., Fan, T., Zhou, P., Niu, X., He, L., 2013. *Houttuynia cordata* Thunb.volatile oil exhibited anti-inflammatory effects in vivo and inhibited nitric oxide and tumor necrosis factor- α production in LPS-stimulated mouse peritoneal macrophages in vitro. *Phytother. Res.* 27, 1629–1639.
- Ludwig, S., Planz, O., 2008. Influenza viruses and the NF- κ B signaling pathway - towards a novel concept of antiviral therapy. *Biol. Chem.* 389, 1307–1312.
- Monto, A.S., Gravenstein, S., Elliott, M., Colopy, M., Schweinle, J., 2000. Clinical signs and symptoms predicting influenza infection. *Arch. Intern. Med.* 160, 3243–3247.
- Poroyko, V., Meng, F., Meliton, A., Afonyushkin, T., Ulanov, A., Semenyuk, E., Latif, O., Tesic, V., Birukova, A.A., Birukov, K.G., 2015. Alterations of lung microbiota in a mouse model of LPS-induced lung injury. *Am. J. Physiol. Lung. Cell. Mol. Physiol.* 309, L76–L83.
- Segal, L.N., Blaser, M.J., 2014. A brave new world: the lung microbiota in an era of change. *Ann. Am. Thorac. Soc.* 1, S21–S27.
- Shinde, V., Bridges, C.B., Uyeke, T.M., Shu, B., Balish, A., Xu, X., Lindstrom, S., Gubareva, L.V., Deyde, V., Garten, R.J., Harris, M., Gerber, S., Vagasky, S., Smith, F., Pascoe, N., Martin, K., Dufficy, D., Ritger, K., Conover, C., Quinlisk, P., Klimov, A., Bresee, J.S., Finelli, L., 2009. Triple-reassortant swine influenza A (H1) in humans in the United States, 2005–2009. *New Engl. J. Med.* 360, 2616–2625.
- Swank, G.M., Deitch, E.A., 1996. Role of the gut in multiple organ failure: bacterial translocation and permeability changes. *World J. Surg.* 20, 411–417.
- Tsay, T.B., Yang, M.C., Chen, P.H., Hsu, C.M., Chen, L.W., 2011. Gut flora enhance bacterial clearance in lung through toll-like receptors 4. *J. Biomed. Sci.* 18, 68–76.
- Wang, J., Li, F., Wei, H., Lian, Z.X., Sun, R., Tian, Z., 2014. Respiratory influenza virus infection induces intestinal immune injury via microbiota-mediated Th17 cell-dependent inflammation. *J. Exp. Med.* 12, 2397–2410.
- Wang, J., Tian, Z., 2015. How lung infection leads to gut injury. *Oncotarget* 6, 42394–42399.
- Xu, Y.Y., Zhang, Y.Y., Ou, Y.Y., Lu, X.X., Pan, L.Y., Li, H., Lu, Y., Chen, D.F., 2015. *Houttuynia cordata* Thunb. polysaccharides ameliorates lipopolysaccharide -induced acute lung injury in mice. *J. Ethnopharmacol.* 173, 81–90.
- Zhang, J., Lu, Y., Chen, D., 2012. Preparation procedures of anti-complementary polysaccharides from *Houttuynia cordata*. *Zhongguo Zhong Yao ZaZhi* 37, 2071–2075 (text in chineses).